# Return to Play After Sports Hernia Surgery

Ho-Rim Choi, MD, Osama Elattar, MD, Vickie D. Dills, PT, DPT, Brian Busconi, MD*

**KEYWORDS**

• Sports hernia • Inguinal disruption • Surgical treatment • Return to sports

**KEY POINTS**

- Despite common presentation in the sports clinic, the definition, clinical characteristics, and treatment of sports hernia (SH) have not been fully understood.
- The clinical spectrum and treatment outcome of SH are reviewed.
- Details of nonoperative and postoperative rehabilitation processes are addressed in this article.

## INTRODUCTION

SH is considered an overuse syndrome presenting with chronic lower abdomen and groin pain. Since Gilmore popularized the syndrome of groin disruption as Gilmore's groin in the early 1990s,[1] this condition has been named various terms, such as SH,[2–6] athletic pubalgia,[7] athletic hernia,[8] Gilmore's groin,[9,10] osteitis pubis, sportsman's hernia,[11,12] sportsmen's groin,[13] hockey groin syndrome,[14] symphysis syndrome,[15] and inguinal disruption.[16] In a recent consensus conference by the British Hernia Society in Manchester, United Kingdom, "inguinal disruption" was proposed as nomenclature for this condition.[17] Despite common presentation in the sports clinic, however, the definition, clinical characteristics, and treatment of SH have not been fully understood. The clinical spectrum of SH, with its treatment outcome and recovery process, is addressed in this article.

## ANATOMY AND PATHOGENESIS

Fibers from the rectus abdominis, conjoint tendon (a fusion of the internal oblique and transversus abdominis), and external oblique merge to form the pubic aponeurosis. This pubic aponeurosis is confluent with the adductor and gracilis origin. SH is considered an injury to muscular and/or fascial attachments of these structures to the anterior pubis. There still is argument, however, regarding the exact anatomic area of disruption because even operative findings of SH repair is obscure.

Disclosure: Authors declare that they have no conflict of interest.
Department of Orthopaedic Surgery, University of Massachusetts, Hahnemann Campus, 281 Lincoln Street, Worcester, MA 01605, USA
* Corresponding author. Department of Orthopaedic Surgery, University of Massachusetts, Hahnemann Campus, 281 Lincoln Street, Worcester, MA 01605.
*E-mail address:* brian.busconi@umassmemorial.org

Clin Sports Med 35 (2016) 621–636
http://dx.doi.org/10.1016/j.csm.2016.05.007 **sportsmed.theclinics.com**
0278-5919/16/$ – see front matter © 2016 Elsevier Inc. All rights reserved.

Downloaded from ClinicalKey.com at Ohio State University Libraries August 26, 2016.
For personal use only. No other uses without permission. Copyright ©2016. Elsevier Inc. All rights reserved.

There are 2 possible explanations regarding the pathogenesis of SH.[7] One is muscle injury or disruption of structures listed previously. Investigators found the SH was associated with a torn external oblique aponeurosis, conjoined tendon, or abdominal wall abnormalities.[1,9,10,14,18,19] Another theory is a defect in the transversalis fascia, which forms the posterior wall of the inguinal canal, resulting in an occult hernia process.[4,8,20,21] In a retrospective analysis of 64 athletes of Australian rules footballers with chronic groin pain, the most common operative finding was a substantially deranged posterior wall of the inguinal canal.[21] Litwin and colleagues[7] concluded that a large tear or multiple small tears must be taking place to form an SH, involving 1 or several muscles in the region, which includes the external oblique aponeurosis, rectus abdominis, conjoined tendon/rectus abdominis interface, or individual muscles that form the conjoined tendon. They also explained that tears to any of these muscles could lead to the operative findings of attenuation, disruption, or retraction of the muscle, thereby weakening the boundaries of the posterior wall of the inguinal canal.[7] Theoretically, the shearing forces are more prominent in athletes with an imbalance between the strong adductor muscles of the thigh and the weak lower abdominal musculature. These forces place stress on the inguinal wall musculature, which ultimately leads to attenuation of local soft tissues.[3,22]

## EPIDEMIOLOGY

The exact incidence of SH is not known, but several studies suggest that it is common in athletes with chronic groin pain.[3] Groin injuries account for approximately 1 in 20 athletic injuries, and groin pain accounts for 1 in 10 patient visits to sport medicine centers.[23] Injuries to the groin account for approximately 5% of all soccer injuries.[9,12]

SH occurs almost exclusively in men. The higher incidence of this condition in men may be explained by a greater level of participation of men in highly competitive sports.[24] An increasing number of female patients, however, are being diagnosed with this injury, ranging 10% to 15%.[25,26] Gender differences in pelvic anatomy, lower extremity alignment, and muscle activation may be another possible explanation for lower incidence of this condition in women.[27,28]

SH is also associated with professional athletes or high-performance school athletes. There is growing trend of occurrence, however, in recreational athletes.[7,24,28,29]

## CLINICAL PRESENTATION

The hallmark symptom of SH is a complaint of gradually increasing activity-related lower abdominal and proximal adductor-related pain. The pain usually is relieved with rest but returns on resumption of sports.[3] Some patients may recall the specific event that initiated the pain; however, the onset is insidious in a majority of the patients.

The pain of lower abdomen or groin is often aggravated by certain movements, such as sudden acceleration, twisting, turning, and cutting or kicking. Soccer, hockey, ice hockey, American football, rugby, or Australian rules football players have a particularly high incidence.[5,7] Some patients complain of aggravated pain by sit-ups, coughing, or sneezing.[8,18,24,28] This pain may radiate to adductor region, perineum, inner thigh, and scrotum or testicular area.[18,25]

A cluster of 5 symptoms and signs are considered the most indicative of SH by Kachingwe and Grech[24]: (1) a subjective complaint of deep groin/lower abdominal pain; (2) pain that is exacerbated with sport-specific activities, such as sprinting, kicking, cutting, and/or sit-ups and is relieved with rest; (3) palpable tenderness over the pubic ramus at the insertion of the rectus abdominis and/or conjoined tendon; (4) pain

Downloaded from ClinicalKey.com at Ohio State University Libraries August 26, 2016.
For personal use only. No other uses without permission. Copyright ©2016. Elsevier Inc. All rights reserved.

with resisted hip adduction at 0°, 45°, and/or 90° of hip flexion; and (5) pain with resisted abdominal curl-up.[3,8,24,28–30]

Initial examination should be started with careful postural evaluation to find out any anterior pelvic tilt. The most common physical findings include localized tenderness at or just above pubic tubercle of the affected side where rectus abdominis attaches. The pain and tenderness are aggravated by resisted sit-ups. Patients usually do not have a detectable true inguinal hernia. Full examination of the hip joint, including range of motion (ROM), is required because joint motion—limiting disease, such as femoroacetabular impingement (FAI), is frequently associated with the HS. It is not uncommon that patients show combined adductor longus area pain and tenderness by resisted leg adduction or direct palpation. Positive pain and tenderness at adductor tendon origin may indicate requirement of additional procedure such as steroid injection or adductor tenotomy.[7,31]

## DIAGNOSIS

Patients with groin pain may have a vast possible causes originating not only from orthopedic neuromuscular structures but also other physiologic system or medical subspecialties, such as general surgery, urology, or gynecology. Careful, thorough history and physical examination are key for accurate diagnosis.

The consensus meeting by the British Hernia Society[17] suggested criteria for diagnosis of inguinal disruption if at least 3 of the 5 clinical signs below are detectable: (1) pinpont tenderness over the pubic tubercle at the point of insertion of the conjoint tendon, (2) palpable tenderness over the deep inguinal ring, (3) pain and/or dilation of the external ring with no obvious hernia evident, (4) pain at the origin of the adductor longus tendon, and (5) dull, diffuse pain in the groin, often radiating to the perineum and inner thigh or across the midline.

## IMAGING

No diagnostic imaging modality is sensitive and specific for the diagnosis of SH. Accordingly, imaging is useful primarily for excluding other pathologic conditions in the differential diagnosis.[2,3]

### *Plain Radiographs*

Plain radiographs should include a well-aligned anteroposterior pelvis and a lateral view of the hip. These may demonstrate symphysis widening or bony erosion, pelvic avulsion fractures, apophyseal injuries, stress fractures, degenerative hip disease, underlying FAI, and dysplasia.

### *MRI*

Many patients with SH frequently reveal nonspecific findings on MRI.[3] Therefore, it is useful for ruling out other causes of groin pain, such as stress fracture, avascular necrosis, or intra-articular hip abnormalities, including labral tears, articular cartilage lesions, or FAI.[8]

MRI is considered, however, the most appropriate diagnostic modality to evaluate SH because of its superiority of soft tissue evaluation. It can demonstrate partial tear or complete rupture of the rectus abdominis muscle or conjoint tendon fibers or bone marrow edema of pubic ramus (**Fig. 1**). Dedicated protocol designed to detect SH should be used when it is suspected clinically.[32,33] Albers and colleagues[34] obtained MRI of 32 athletes with pubalgia and found abnormalities in pubic symphysis (21/30); abdominal wall (27/30); groin musculature, including rectus abdominis (21/30); and

Downloaded from ClinicalKey.com at Ohio State University Libraries August 26, 2016.
For personal use only. No other uses without permission. Copyright ©2016. Elsevier Inc. All rights reserved.

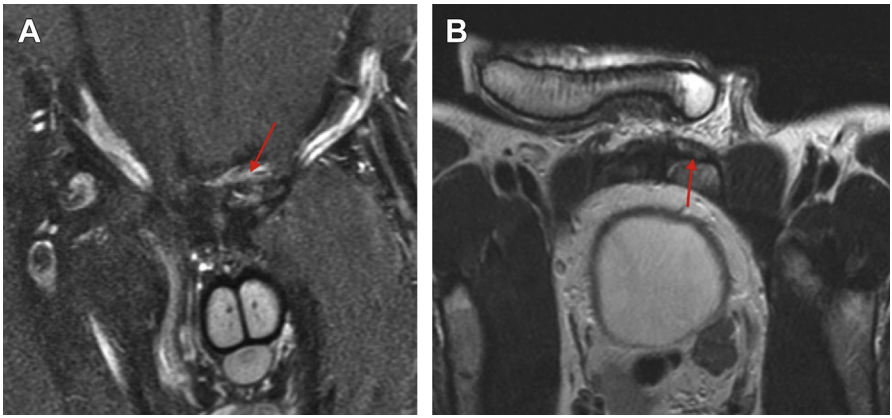


**Fig. 1.** (*A*) Coronal STIR and (*B*) oblique axial T2 images of pelvis MRI in a 22-year-old male patient show soft tissue signal change demonstrating rupture of left rectus abdominis muscle (*arrow*).

adductor muscle group (18/30). Zoga and colleagues[35] investigated MRI in 141 patients with groin pain and reported 68% of sensitivity and 100% specificity for rectus abdominis tendon injury and 86% sensitivity and 89% of specificity for adductor tendon injury.

### *Ultrasound*

Dynamic high-resolution ultrasound can be a useful noninvasive modality for evaluating SH as the patient actively strains during the procedure. Orchard and colleagues[36] investigated 35 professional Australian footballers and found that dynamic ultrasound examination was able to detect inguinal canal posterior wall deficiency in 21 of 35 patients. Advantages of ultrasound examination are that it is a less expensive than MRI, noninvasive modality but a disadvantage is that it is highly operator dependent with variable reproducibility.[8]

## DIFFERENTIAL DIAGNOSIS

There are several causes of chronic lower abdomen and groin pain that need to be differentiated from SH: disorders of the hip joint, injury to muscles of the thigh or abdominal wall, and even genitourinary or intra-abdominal disease. Before making a diagnosis of SH, many of these conditions should be differentiated by careful history, physical examination, and imaging studies[37] (**Box 1**).

### *Femoroacetabular Impingement*

FAI is a condition that proximal femoral neck abuts acetabulum with ROM, especially in flexion. Patients usually present with activity-related groin or hip pain with limited hip flexion and internal rotation. Physical examination typically shows groin pain, which is elicited by anterior impingement test. Plain radiographs show decreased head-to-neck ratio, aspherical femoral head, or overhanging of acetabular rim. MRI is the best modality to evaluate associated lesion of acetabular labrum and articular cartilage. Surgical correction of bony deformity of cam or/and pincer combined with labral repair is indicated for symptomatic patients who are not responsive to conservative management.

Downloaded from ClinicalKey.com at Ohio State University Libraries August 26, 2016.
For personal use only. No other uses without permission. Copyright ©2016. Elsevier Inc. All rights reserved.

**Box 1**
**Differential diagnosis for groin pain**

*Hip joint*
- Acetabular labral tear
- FAI
- Adductor injury
- Osteoarthritis
- Avascular necrosis
- Femoral neck stress fracture

*Muscle and tendon*
- Sports hernia
- Adductor strain/tendinitis
- Rectus femoris strain/tear
- Iliopsoas strain/tendinitis

*Surrounding bone lesion*
- Osteitis pubis
- Pubic ramus fracture
- Avulsion fracture: avulsion anterior superior iliac spine, avulsion anterior inferior iliac spine

*Intra-abdominal*
- Endometriosis
- Ovarian cystic disease
- Pelvic inflammatory disease
- Crohn disease

*Abdominal hernia*
- Inguinal hernia
- Femoral hernia

*Genitourinary*
- Epididymitis
- Prostatitis
- Testicular tumors
- Urethritis

### *Adductor Strain*

Pulled groin commonly occurs in 10% to 30% of soccer and hockey players by strong eccentric contraction of adductors during play. Pain develops immediately after an acute injury and many patients shows pain and decreased muscle strength with resisted leg adduction. MRI shows adductor muscle injury, such as muscle edema, hemorrhage, or occasional bony avulsion in juvenile players. Nonoperative management followed by rehabilitation and gradual return to sports is suggested.

Downloaded from ClinicalKey.com at Ohio State University Libraries August 26, 2016.
For personal use only. No other uses without permission. Copyright ©2016. Elsevier Inc. All rights reserved.

### *Osteitis Pubis*

Osteitis pubic is an inflammation of the pubic symphysis caused by repetitive microtrauma by sports, such as soccer, hockey, football and running involving kicking/adduction/abduction. Symptom is vague, ill-defined pain at anterior pelvis region. The unique physical finding is localized tenderness directly over the pubis symphysis. Plain radiographs are frequently show osteolytic pubis with bony erosion. This is a self-limiting process and may take several months to resolve by nonoperative management.

## TREATMENT

In general, many SH patients visit orthopedic sports clinics and then undergo surgery by hernia surgeons after consultation with general surgery. Physiotherapy shares an important role for both nonoperative and postoperative treatment of rehabilitation. Radiology also performs a critical role to obtain detail information of anatomic structure based on imaging studies. Therefore, a multidisciplinary therapeutic approach is necessary for best outcome. In addition, multiple factors should be addressed when treatment decisions are made: degree of limitation and athletes' ability to participate in the sports, sports seasons and upcoming athletic events, response to prior treatment modalities, and level of athletes.[38]

### *Nonsurgical Treatment*

It is agreed that surgery is not always indicated and nonoperative management should be attempted for all athletes as the first line of treatment if an athlete is in season and able to function at a high level despite pain: 4-week to 8-week trial of rest, oral analgesics and anti-inflammatory medications, steroid injection to the rectus abdominis insertion or the adductor longus origin, and physical therapy.[7,17,38]

Physical therapy concentrates on stretching/strengthening, core stabilization, postural retraining, and restoration of balance to the abdominal wall, hip, and pelvis muscles. Aggressive stretching and attempts at improving ROM are not recommended because they can result in increased hip pain with underlying hip pathology, such as labral lesion or FAI.[5,29] Larson and Lohnes[39] outlined a 4-phase rehabilitation protocol for athletes with chronic groin pain. Phase 1 (weeks 1 and 2) focuses on massage and stretching. Phase 2 (weeks 3 and 4) emphasizes abdominal muscle strengthening. In phase 3 (week 5), functional activities, including running, are initiated. In phase 4 (week 6), the athlete returns to sport-specific activities.[39] At approximately 10 weeks to 12 weeks after the start of conservative treatment and when the athlete is pain-free, return to sports competition is generally attempted.

Ultrasound-guided steroid injection into the rectus abdominis insertion site, conjoined tendon, or adductor tendon can be a useful nonoperative management option during the season if an athlete wants to keep playing. In the authors' institute, in-season or preseason nonoperative management starts with 1 weeks to 2 weeks trial of rest with selective steroid or platelet-rich plasma injections to the rectus abdominis insertion and/or the adductor longus origin. At the completion of the rest period, an exercise program emphasizing strengthening, soft tissue and joint mobilization, and dynamic stability exercises is followed with cardiovascular training (**Table 1**).

In general, however, SH is known to be poorly responsive to nonoperative treatment and there are few data evaluating the efficacy of nonoperative treatment.[2,3,8,12,15,40] Paajanen and colleagues[41] performed a randomized, prospective comparative study between 30 operative versus 30 physiotherapy for sportsman's hernia and demonstrated that operative repair was more effective than nonoperative treatment to

Downloaded from ClinicalKey.com at Ohio State University Libraries August 26, 2016.
For personal use only. No other uses without permission. Copyright ©2016. Elsevier Inc. All rights reserved.

**Table 1**
**Rehabilitation protocol for nonoperative management with/without corticosteroid injection**

| In-Season | Week | Postseason |
|---|---|---|
| • Rest (injected) structures | 1–2 | • Rest (injected) structures |
| • ROM lumbar and bilateral hip joints<br>• Gluteal muscle and anterior pelvis stabilization<br>○ Hip hikes<br>○ Abdominal bracing in hook lying<br>○ Front and side planks<br>○ Quadruped alternating upper and lower extremity on compliant and noncompliant surfaces<br>• Stationary bike without resistance | 3 | • ROM lumbar and bilateral hip joints<br>• Gluteal muscle and anterior pelvis stabilization<br>○ Hip hikes<br>○ Abdominal bracing in hook lying<br>○ Front and side planks<br>○ Quadruped alternating upper and lower extremity on compliant and noncompliant surfaces<br>• Stationary bike without resistance |
| • Continue week 3 exercises<br>• Flexion only straight leg raises; progress to multiplane<br>• Supine hip extension with knee at 0 and 90°<br>• Single-leg balance exercises<br>• Bridging<br>• Wall squats at 45°–90° | 4 | • Continue week 3 exercises<br>• Flexion only straight leg raises; progress to multiplane<br>• Supine hip extension with knee at 0 and 90°<br>• Single-leg balance exercises<br>• Bridging<br>• Wall squats at 45°–90° |
| • Resistance walking, pushing, pulling<br>• Return-to-running/jumping program (single plane)<br>• Box jumps<br>• Tilt board, agility ladder, and BOSU drills | 5 | • Continue weeks 3–4 exercises |
| • Progress core stabilization exercises<br>• Increase resistive exercise as tolerated<br>• Initiate sport-specific exercise program | 6 | • Continue weeks 3–4 exercises |
| • Continue with progressive sport-specific program<br>• Gradual return to sport through progressive practice participation | 7–8 | • Progress core stabilization exercises<br>• Increase resistive exercise as tolerated<br>• Initiate sport-specific exercise program |
| • Return to play | 9 | • Gradual return to sport through progressive practice participation |

decrease chronic groin pain after 1 month and up to 12 months of follow-up; 27 of 30 athletes (90%) who underwent operation returned to sports activities after 3 months of convalescence compared with 8 (27%) of the 30 athletes in the nonoperative group.[41] On the other hand, Kachingwe and Grech[24] suggested that conservative management, including manual therapy, could be a viable option in the management of athletes with an athletic pubalgia based on their decision making.[24]

### *Surgical Treatment*

Surgical exploration and repair should be considered when nonoperative treatment has failed and the athlete continues to experience pain and disability during the season. Higher-level athletes who completed the season but struggled with chronic pain might be considered for surgery during off season. A variety of surgical techniques have been reported in the literature, including open repair of the rectus abdominis, external oblique, transversus abdominis or transversalis fascia, repairs with mesh

Downloaded from ClinicalKey.com at Ohio State University Libraries August 26, 2016.
For personal use only. No other uses without permission. Copyright ©2016. Elsevier Inc. All rights reserved.

reinforcement, laparoscopic repairs, miniopen repairs, and broad pelvic floor repairs with or without adductor releases.

### *Open surgeries*

Gilmore[9] reported repair of torn external oblique aponeurosis, conjoined tendon, and dehiscence between conjoined tendon and inguinal ligaments for more than 1000 soccer players. The surgery was successful in 97% of cases with average player return to league football within 6 weeks.[9] Hackney[4] reported excellent results of surgical repair of the posterior inguinal wall for SH; 14 of 15 patients (87%) could successfully return to full sporting activity after their postoperative protocol: stretching and non–weight-bearing exercise, such as swimming or cycling after 3 weeks, and running at 4 to 5 weeks, daily training at 6 weeks.[4] Meyers and colleagues[28] reported outcome of the pelvic floor repair in 175 high-performance athletes, which involved open broad surgical reattachment of the inferolateral edge of the rectus abdominis muscle with its fascial investment to the pubis and adjacent anterior ligaments with/without adductor longus release.[19,28] They reported 88% of patients were performing at or above their preinjury levels of performance at 3 months after surgery and 96% at 6 months. Jans and colleagues[42] analyzed outcome of 241 male athletes of chronic sportsman's hernia. They underwent surgical intervention with reinforcement of the posterior inguinal wall and tenotomy of the adductors. More than 90% of 162 athletes could achieve satisfactory results.[42] Ahumada and colleagues[29] reported 12 patients with athletic pubalgia who underwent open inguinal repair, with 9 reinforced with mesh. Results were 83.3% excellent and 16.7% satisfactory, and all returned to sports by median 4 months of follow-up.[29] In the authors' institute, open suture repair is preferred focusing on (1) repair and retensioning of the rectus abdominis to the pubis and broadening of its insertion, (2) stabilization of the conjoined tendon/rectus abdominis interface, and (3) reinforcement of the posterior wall of the inguinal canal.[7]

Surgery is performed by a general surgeon with a special interest in abdominal wall disorders and an orthopedic sports medicine specialist together as a multidisciplinary team approach. A short groin incision along skin crease is made and external oblique muscle is exposed through subcutaneous fat dissection. This muscle is opened in the direction of its fibers and separated from underlying structures. The spermatic cord is retracted inferiorly to expose the posterior wall of the inguinal canal. Attenuation and bulging of the posterior wall or disruption of the rectus abdominis or conjoined tendon is repaired at this point (**Fig. 2**A). At the beginning of the repair, the pubic tubercle is roughened with electrocautery to create an inflammatory surface and the lateral edge of rectus is brought down to the periosteum of the tubercle with 1 or 2 stitches using Orthocord (DePuy Orthopaedics, Warsaw, Indiana). The edge of rectus is brought down to the Cooper ligament with 1 stitch, followed by 1 interrupted suture approximating the conjoined tendon/rectus abdominis interface with the shelving portion of the ilioinguinal ligament. At this point, 1 or 2 reinforcing stitches extend laterally, pulling conjoined tendon to shelving portion (**Fig. 2**B). All nerves are preserved. The cord is then dropped back into position, and the external oblique aponeurosis closed as well as the skin and subcutaneous tissues.[7] If the adductor longus symptom is involved, it can either be injected with steroid or platelet-rich plasma, or tendon release/lengthening is performed at the time of surgery.

### *Laparoscopic surgeries or minimal repair*

Laparoscopic treatment offers the potential advantage of a more rapid recovery and return to sport than does open hernia repair. Genitsaris and colleagues[20] reviewed 131 athletes with chronic groin pain who underwent laparoscopic repair of deficiency

Downloaded from ClinicalKey.com at Ohio State University Libraries August 26, 2016.
For personal use only. No other uses without permission. Copyright ©2016. Elsevier Inc. All rights reserved.

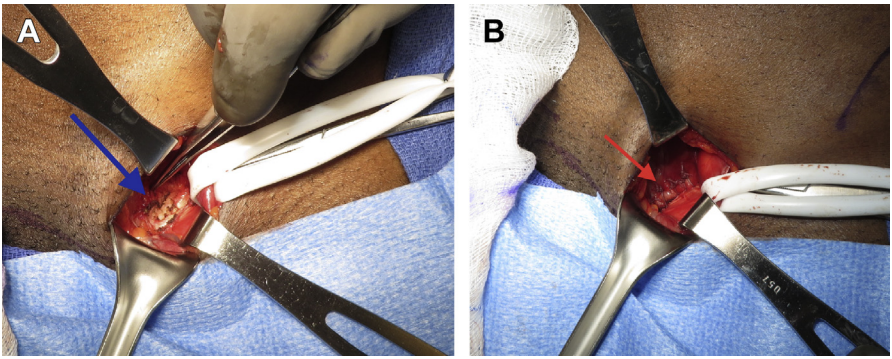


**Fig. 2.** A 25-year-old professional football player shows (*A*) attenuated rectus abdominis muscle insertion to the pubic tubercle (*arrow*). (*B*) Rectus abdonimis was retensioned with reinforcement of posterior inguinal wall (*arrow*).

of the posterior inguinal wall. All patients were able to back to full sporting activities within 2 to 3 weeks and there was only 1 recurrence (0.76%) after a mean follow-up of 5 years.[20] Rossidis and colleagues[43] reported 100% successful return to full sports-related activity of 54 athlete patients treated by laparoscopic extraperitoneal inguinal hernia repair with synthetic mesh combined with ipsilateral adductor longus tenotomy. All patients were able to return to full sports-related activity in 24 days (range 21–28 days).[43] van Veen and colleagues[30] reported that 55 professional and semiprofessional sportsmen with chronic groin pain were treated by endoscopic total extraperitoneal mesh placement, and all the athletes could return to their normal sports level within 3 months after the operation.[30] In a comparative study between open versus laparoscopic repairs for groin disruption, the open repairs could restart full-contact training at a median 5 weeks (range 1–6) versus 3 weeks (range 1–9) for the laparoscopic repairs.[44]

On the other hand, Economopoulos and colleagues[45] compared the outcome of 14 modified Bassini repairs and 14 minimal repair techniques. They found that the patients in the minimal repair group returned to sports earlier (5.6 weeks vs 25.8 weeks) and higher success rates of returning to sports at their preinjury level of play (13/14 vs 9/14).

### *Concurrent Management of Associated Pathology*

Because there is increasing awareness of an association between ROM-limiting hip disorders, such as FAI or intra-articular hip pathology and SH in athletes, it is important to consider concurrent management of those lesions.[37,46,47] Hammoud and colleagues[46] reported that 39% of patients who underwent arthroscopic surgery for symptomatic FAI resolved athletic pubalgia symptoms and emphasized drawing attention to the overlap of these 2 diagnoses.[46] Larson and colleagues[37] evaluated follow-up outcome of 37 hips diagnosed with both symptomatic athletic pubalgia and symptomatic intra-articular hip joint pathology. They found surgical management of both disorders concurrently or in a staged manner led to improved postoperative outcome scoring and an unrestricted return to sporting activity in 89% of hips, whereas the hips only addressed either the athletic pubalgia or intra-articular hip pathology showed suboptimal outcomes.[37]

In addition, treatment of a contracted or overdeveloped adductor muscle also need to be addressed. Investigators recommend adductor tenotomy combined with hernia repair when symptomatic adductor abnormality cannot be corrected

Downloaded from ClinicalKey.com at Ohio State University Libraries August 26, 2016.
For personal use only. No other uses without permission. Copyright ©2016. Elsevier Inc. All rights reserved.

preoperatively.[29,31,43] The improvement of adductor pain after SH repair suggests that adductor tendinitis may be a secondary phenomenon to the SH or initial injury. If the theory regarding an imbalance between the strong adductors and weak abdominal muscles is true, then additional procedure, such as adductor release, adductor tendon injection, or osteoplasty for FAI, may be a reasonable measurement to decrease symptoms and protect the pelvic floor procedure.[7,8]

## RETURN TO SPORTS AFTER SURGERY

Both nonoperative and postoperative treatment options share the goal of returning the athlete back to pain-free activity. There is little research available, however, to reference for rehabilitation guidelines and creation of therapeutic plan in regard to timing back to sports activities after surgery or nonoperative management.[48]

The consensus meeting by the British Hernia Society[17] suggested that appropriate preoperative and postoperative care should allow a full return to activity within 4 weeks to 8 weeks from the date of surgery.[17] They also emphasized that close liaison between the treating clinicians and the physiotherapy team is required for the preoperative and postoperative rehabilitation. Litwin and colleagues[7] reported their postoperative rehabilitation and recovery process after open reattachment of the rectus and reinforcement of the posterior wall of the inguinal canal. The patient is allowed weight bearing as tolerated with relative rest for the first 10 days and gentle hip ROM. Closed-chain lower extremity exercises are permitted for the next 2 weeks. At approximately week 4, light abdominal core exercises are added, and at approximately week 5, sport-specific activity is advanced as tolerated. Full return to sport is at approximately 6 weeks. Gilmore[9] analyzed groin pain in soccer athletes and suggested intensive groin disruption rehabilitation program after surgical repair: week 1, walk 2 times a day; week 2, jog in straight lines and start adductor exercises; week 3, run in straight lines and increase adductor exercises; and week 4, sprint and start kicking; may play. The average player was reported to be able to return to league football within 6 weeks.[9] Biedert and colleagues[15] treated 24 athletes of chronic symphysis syndrome by spreading of the lateral border of the sheath of the rectus abdominis muscle or reconstruction of the muscle together with an epimysial adductor release. The patients started postoperative physical therapy and rehabilitation on the first day after surgery with immediate isometric contractions of the abdominal and adductor muscles under physical therapy control. Full training was allowed after 6 weeks to 8 weeks when the athlete was completely pain-free, and competition was allowed after 10 to 12 weeks. Full sports activity was noted in 23 of 24 athletes at a mean of 6.6 years posttreatment.[15] Hemingway and colleagues[49] described a 6-week post–open SH repair rehabilitation program, which involved both attending physiotherapy once a week and a standardized home exercise program: week 1, isometric abdominals and hip exercises, walk increased by 5 min/d, and stairs; week 2: active exercises for hips, transverse and oblique abdominals, and exercise bike; week 3: flexibility work, Thera-Band hip exercises, transverse and oblique abdominals, jogging, and swimming; week 4: running forward, progressing to abdominal work, and low upper body weights; week 5: sprinting, running in all directions, light ball skills, kicking, abdominals, and gradual return to training; and week 6: full training, match play, and return to play. They could achieve the most significant improvement of abdominal obliques strength by rehabilitation.

In the authors' institute, athletes are recommended to rest for 1 week to 2 weeks after surgery, anticipating wound healing and pain control. Normal passive hip ROM with isometric abdominal and hip exercises is restored this phase (phase I) (**Box 2**).

Downloaded from ClinicalKey.com at Ohio State University Libraries August 26, 2016.
For personal use only. No other uses without permission. Copyright ©2016. Elsevier Inc. All rights reserved.

**Box 2**
**Rehabilitation protocol after surgical repair of sports hernia (phase I)**

Day 1 through week 2: rest, tendinous healing and remodeling

*Goals:*

- Protect surgical site
- Wound care
- Pain control
- Edema reduction
- Improve soft tissue flexibility
- Restore normal passive hip ROM
- Educate patient on precautions, restrictions, and plan of care

*Rehabilitation*

- Gentle, passive ROM to bilateral hip joints; avoid painful end ranges and excessive hip abduction and extension, which stress the surgical sites
- Joint mobilization of the lumbar spine grades II–III for pain control and lumbar mobility
  - Hip anterior glide mobilization in supine
  - Hip posterior glide mobilization in supine
  - Central lumbar mobilization
  - Anterior ilium rotation mobilization
  - Posterior ilium rotation mobilization
- Soft tissue mobilization of lumbar paraspinal muscles
- Scar mobilization as soon as incision sutures are removed; deep transverse friction massage, instrument assisted soft tissue mobilization
- Stationary bike without resistance, avoid trunk hyperextension
- Patient education for pelvic neutral in sitting and standing
- Restore normal walking gait patterns
- Avoid activities, which increase intra-abdominal pressure
- No lifting or other activities that increase abdominal pressures
- Ice 15 minutes every 2 to 4 hours for the first 24 to 48 hours

Progressive exercise is performed focusing on hip ROM, core strengthening, postural exercise, and improving biomechanics in 3 weeks to 4 weeks (phase II) (**Box 3**). Sport-specific movements with plyometric exercise and agility drill starts in 5 weeks to 8 weeks after surgery to return to sports (phase III) (**Box 4**).

Success rates to return to sports have been reported ranging from 80% to 100%.[4,5,13,20,26,28,50–52] According to a systematic literature review, overall postsurgical recovery time based on return-to-sports activity for patients who underwent open repair was 17.7 weeks compared with 6.1 weeks for laparoscopic repairs.[2] It seems there are some common concepts among most surgeons regarding timing back-to-sports activities after surgery of SH, despite that direct comparison of these outcomes is difficult because of different patient populations and a variety of surgical techniques. In general, most athletes return to sports participation within 2 to 6 weeks after laparoscopic repair and within 1 to 6 months after open repair.[3,28,29]

Downloaded from ClinicalKey.com at Ohio State University Libraries August 26, 2016.
For personal use only. No other uses without permission. Copyright ©2016. Elsevier Inc. All rights reserved.

**Box 3**
**Rehabilitation protocol after surgical repair of sports hernia (phase II)**

Weeks 3 to 4: continue to increase hip ROM, core strength, improve biomechanics

*Goals*

- Target strengthening and neuromuscular re-education with a focus on timing and recruitment patterns during functional movements
- Identify muscle imbalances, postural deviations, and muscular compensations
- Advance core strength and stability
- Advance cardiovascular training

*Rehabilitation: monitor patient pain levels and progress as tolerated*

- Stretching to increase and restore flexibility of all lower extremity muscle groups including hamstrings, adductors, gluteal muscles, hip flexors, ankle dorsiflexors, and quadriceps
- Core strengthening/core stability exercises with emphasis on gluteus medius, gluteus maximus, TA, and multifidus
  - Isometric abdominals with focus on TA and obliques to facilitate TA recruitment; start in supine and progress to quadruped, kneeling and half-kneeling positions
  - Dead bugs
  - Glute bridges progressing to glute bridges with resistance bands
  - Front and side planks
  - Double-leg and single-leg bridging
  - Rocker board drills
- Progressive resistive exercises
  - Straight leg raises for hip flexors
  - Wall squats for hamstrings and quadriceps
  - Heel raises for gastroc/soleus
  - Lateral band walks for hip abductors; maintain lumbar neutral control
  - PNF diagonals with sport cord
  - Crossband core work initiated in supine and progressed to standing
- Straight plane motion in weight bearing
  - Forward lunges (avoid deep lunges)
  - Single-leg dead lifts
  - Leg presses
  - Wall slides at less than 90° progressing to 90° while extending hold times
  - Step-ups and step-downs; focus on eccentric quad control and proper pelvic alignment
- Proprioceptive training
  - Single-leg balance exercise to include cone taps, single-leg ball toss
  - Exercises on unstable, noncompliant surfaces, such as foam pads, tilt board, BOSU ball
  - Balance reach exercises with both lower and upper extremities
  - Single and multiplane wobble board drills
- Cardiovascular training
  - Continue with seated or recumbent bike adding resistance in pain-free intensities; seated recruits gluteals more than the recumbent bike
  - Elliptical (pain-free)
  - Stable surface or treadmill walking

*Abbreviations:* PNF, proprioceptive neuromascular facilitation; TA, transversus abdominis.

## SUMMARY

Groin pain can be presented as a complex clinical feature. It may be related to injury of the soft tissue, bone, or joints from an orthopedic, neurologic, urologic, or general surgical issue, which essentially requires multidisciplinary approach. Proper evaluation by

Downloaded from ClinicalKey.com at Ohio State University Libraries August 26, 2016.
For personal use only. No other uses without permission. Copyright ©2016. Elsevier Inc. All rights reserved.

**Box 4**
**Rehabilitation protocol after surgical repair of sports hernia (phase III)**

Weeks 5 to 8: return-to-sports/plyometric exercises

*Goals*

- Prescribe sport-specific movements and speeds to prepare and strengthen the involved tissue for the forced couples created during sport-specific movements
- Progress to running on uneven surfaces progressing to an intensity required for specific sport
- Return to full play without pain

*Rehabilitation: exercise in all 3 planes of motion. Implement return-to-running and sport-specific activities in both open and closed kinetic chain. Monitor patient pain levels and progress as tolerated.*

- Core strengthening/core stability exercises
  - 3-Way planks
  - Prone physioball walkouts
  - Dynamic planks
  - Resisted core exercise using medicine balls, sports cords, weights
  - Advanced cross-band resisted core exercises
- Triplane weight-bearing exercises
  - Forward and lateral lunges
  - TRX/Rip 60 double-leg and single-leg squats
  - Resisted band ambulation forward, backward and lateral
  - Speed skaters progressing to resisted speed skaters
  - Slide board drills
- Proprioceptive training
  - Sport cord arcs
  - Sport forward and backward shuffles
  - Single-leg ladder drills
  - Single-leg BOSU drills
- Cardiovascular training
  - Return to running on even, flat ground
  - Line jumps/box jumps
  - Progress to running on uneven surfaces progressing to an intensity required for specific sport
  - Sport-specific sprinting, endurance running, changes in direction
  - Ladder drills
  - High knees, butt kicks, bounding, high skipping, bear crawls
- Plyometric exercises
  - BOSU drills
  - Box jumps
  - Medicine ball tosses/lunges
  - Weighted rope drills
  - Cone drills
- Agility drills
  - Straight running at a steady pace, 20 to 30 minutes
  - High knee drills
  - Lateral running in crouched position
  - Backward running
  - Vertical jumping
  - Stair climbing
  - Carioca drills
  - Line touch drills
  - Figure-8 running
  - Run and cut

Downloaded from ClinicalKey.com at Ohio State University Libraries August 26, 2016.
For personal use only. No other uses without permission. Copyright ©2016. Elsevier Inc. All rights reserved.

- Sport-specific drills to include
  - Court sports: vertical leaping, box out drills, initiate plant/pivot, change direction, stop/start
  - Soccer: cone dribbling, initiate plant/pivot, change directions, stop/start, increase training/sprinting
  - Hockey: slide board drills with and without stick, initiate start/stop, skating practice drills with team, shooting
  - Football: plant/pivot, change directions, short sprints, long sprints, lateral bounds, squat jumps, crossover drills

careful history and meticulous physical examination is the first step for an accurate diagnosis. Surgical intervention, both open and laparoscopic, is frequently required, leading to excellent results in most reported studies. Well-designed research studies are warranted to better understand the pathogenesis and short-term and long-term outcomes based on therapeutic measurement and to establish most effective rehabilitation and preventive training protocol.

## REFERENCES


1. Gilmore J. Gilmore's groin: ten years experience of groin disruption- a previously unsolved problem in sportsmen. Sports Med Soft Tissue Trauma 1991;1(3):12–4.
2. Caudill P, Nyland J, Smith C, et al. Sports hernias: a systematic literature review. Br J Sports Med 2008;42(12):954–64.
3. Farber AJ, Wilckens JH. Sports hernia: diagnosis and therapeutic approach. J Am Acad Orthop Surg 2007;15(8):507–14.
4. Hackney RG. The sports hernia: a cause of chronic groin pain. Br J Sports Med 1993;27(1):58–62.
5. Larson CM. Sports hernia/athletic pubalgia: evaluation and management. Sports Health 2014;6(2):139–44.
6. Minnich JM, Hanks JB, Muschaweck U, et al. Sports hernia: diagnosis and treatment highlighting a minimal repair surgical technique. Am J Sports Med 2011;39(6):1341–9.
7. Litwin DE, Sneider EB, McEnaney PM, et al. Athletic pubalgia (sports hernia). Clin Sports Med 2011;30(2):417–34.
8. Swan KG Jr, Wolcott M. The athletic hernia: a systematic review. Clin Orthop Relat Res 2007;455:78–87.
9. Gilmore J. Groin pain in the soccer athlete: fact, fiction, and treatment. Clin Sports Med 1998;17(4):787–93, vii.
10. Williams P, Foster ME. 'Gilmore's groin'–or is it? Br J Sports Med 1995;29(3):206–8.
11. Fon LJ, Spence RA. Sportsman's hernia. Br J Surg 2000;87(5):545–52.
12. Moeller JL. Sportsman's hernia. Curr Sports Med Rep 2007;6(2):111–4.
13. Muschaweck U, Berger L. Minimal Repair technique of sportsmen's groin: an innovative open-suture repair to treat chronic inguinal pain. Hernia 2010;14(1):27–33.
14. Irshad K, Feldman LS, Lavoie C, et al. Operative management of "hockey groin syndrome": 12 years of experience in National Hockey League players. Surgery 2001;130(4):759–64 [discussion: 64–6].
15. Biedert RM, Warnke K, Meyer S. Symphysis syndrome in athletes: surgical treatment for chronic lower abdominal, groin, and adductor pain in athletes. Clin J Sport Med 2003;13(5):278–84.


Downloaded from ClinicalKey.com at Ohio State University Libraries August 26, 2016.
For personal use only. No other uses without permission. Copyright ©2016. Elsevier Inc. All rights reserved.

16. Sheen AJ, Iqbal Z. Contemporary management of 'Inguinal disruption' in the sportsman's groin. BMC Sports Sci Med Rehabil 2014;6:39.
17. Sheen AJ, Stephenson BM, Lloyd DM, et al. 'Treatment of the sportsman's groin': British Hernia Society's 2014 position statement based on the Manchester Consensus Conference. Br J Sports Med 2014;48(14):1079–87.
18. Nam A, Brody F. Management and therapy for sports hernia. J Am Coll Surg 2008;206(1):154–64.
19. Taylor DC, Meyers WC, Moylan JA, et al. Abdominal musculature abnormalities as a cause of groin pain in athletes. Inguinal hernias and pubalgia. Am J Sports Med 1991;19(3):239–42.
20. Genitsaris M, Goulimaris I, Sikas N. Laparoscopic repair of groin pain in athletes. Am J Sports Med 2004;32(5):1238–42.
21. Polglase AL, Frydman GM, Farmer KC. Inguinal surgery for debilitating chronic groin pain in athletes. Med J Aust 1991;155(10):674–7.
22. LeBlanc KE, LeBlanc KA. Groin pain in athletes. Hernia 2003;7(2):68–71.
23. Suarez JC, Ely EE, Mutnal AB, et al. Comprehensive approach to the evaluation of groin pain. J Am Acad Orthop Surg 2013;21(9):558–70.
24. Kachingwe AF, Grech S. Proposed algorithm for the management of athletes with athletic pubalgia (sports hernia): a case series. J Orthop Sports Phys Ther 2008; 38(12):768–81.
25. Garvey JF, Read JW, Turner A. Sportsman hernia: what can we do? Hernia 2010; 14(1):17–25.
26. Meyers WC, McKechnie A, Philippon MJ, et al. Experience with "sports hernia" spanning two decades. Ann Surg 2008;248(4):656–65.
27. Brophy RH, Backus S, Kraszewski AP, et al. Differences between sexes in lower extremity alignment and muscle activation during soccer kick. J Bone Joint Surg Am 2010;92(11):2050–8.
28. Meyers WC, Foley DP, Garrett WE, et al. Management of severe lower abdominal or inguinal pain in high-performance athletes. PAIN (Performing Athletes with Abdominal or Inguinal Neuromuscular Pain Study Group). Am J Sports Med 2000;28(1):2–8.
29. Ahumada LA, Ashruf S, Espinosa-de-los-Monteros A, et al. Athletic pubalgia: definition and surgical treatment. Ann Plast Surg 2005;55(4):393–6.
30. van Veen RN, de Baat P, Heijboer MP, et al. Successful endoscopic treatment of chronic groin pain in athletes. Surg Endosc 2007;21(2):189–93.
31. Van Der Donckt K, Steenbrugge F, Van Den Abbeele K, et al. Bassini's hernial repair and adductor longus tenotomy in the treatment of chronic groin pain in athletes. Acta Orthop Belg 2003;69(1):35–41.
32. Omar IM, Zoga AC, Kavanagh EC, et al. Athletic pubalgia and "sports hernia": optimal MR imaging technique and findings. Radiographics 2008;28(5):1415–38.
33. Palisch A, Zoga AC, Meyers WC. Imaging of athletic pubalgia and core muscle injuries: clinical and therapeutic correlations. Clin Sports Med 2013;32(3):427–47.
34. Albers SL, Spritzer CE, Garrett WE Jr, et al. MR findings in athletes with pubalgia. Skeletal Radiol 2001;30(5):270–7.
35. Zoga AC, Kavanagh EC, Omar IM, et al. Athletic pubalgia and the "sports hernia": MR imaging findings. Radiology 2008;247(3):797–807.
36. Orchard JW, Read JW, Neophyton J, et al. Groin pain associated with ultrasound finding of inguinal canal posterior wall deficiency in Australian Rules footballers. Br J Sports Med 1998;32(2):134–9.

Downloaded from ClinicalKey.com at Ohio State University Libraries August 26, 2016.
For personal use only. No other uses without permission. Copyright ©2016. Elsevier Inc. All rights reserved.

37. Larson CM, Pierce BR, Giveans MR. Treatment of athletes with symptomatic intra-articular hip pathology and athletic pubalgia/sports hernia: a case series. Arthroscopy 2011;27(6):768–75.
38. Larson CM, Birmingham PM, Oliver SM. Athletic Publagia. In: Miller MD, Thompson SR, editors. DeLee & Drez's orthopaedic sports medicine. 4th edition. Saunders; 2014. p. 966–74, 74.e2.
39. Larson CM, Lohnes JH. Surgical management of athletic publagia. Oper Tech Sports Med 2002;10:228–32.
40. Holmich P, Uhrskou P, Ulnits L, et al. Effectiveness of active physical training as treatment for long-standing adductor-related groin pain in athletes: randomised trial. Lancet 1999;353(9151):439–43.
41. Paajanen H, Brinck T, Hermunen H, et al. Laparoscopic surgery for chronic groin pain in athletes is more effective than nonoperative treatment: a randomized clinical trial with magnetic resonance imaging of 60 patients with sportsman's hernia (athletic pubalgia). Surgery 2011;150(1):99–107.
42. Jans C, Messaoudi N, Pauli S, et al. Results of surgical treatment of athletes with sportsman's hernia. Acta Orthop Belg 2012;78(1):35–40.
43. Rossidis G, Perry A, Abbas H, et al. Laparoscopic hernia repair with adductor tenotomy for athletic pubalgia: an established procedure for an obscure entity. Surg Endosc 2015;29(2):381–6.
44. Ingoldby CJ. Laparoscopic and conventional repair of groin disruption in sportsmen. Br J Surg 1997;84(2):213–5.
45. Economopoulos KJ, Milewski MD, Hanks JB, et al. Sports hernia treatment: modified bassini versus minimal repair. Sports Health 2013;5(5):463–9.
46. Hammoud S, Bedi A, Magennis E, et al. High incidence of athletic pubalgia symptoms in professional athletes with symptomatic femoroacetabular impingement. Arthroscopy 2012;28(10):1388–95.
47. Munegato D, Bigoni M, Gridavilla G, et al. Sports hernia and femoroacetabular impingement in athletes: a systematic review. World J Clin Cases 2015;3(9):823–30.
48. Ellsworth AA, Zoland MP, Tyler TF. Athletic pubalgia and associated rehabilitation. Int J Sports Phys Ther 2014;9(6):774–84.
49. Hemingway AE, Herrington L, Blower AL. Changes in muscle strength and pain in response to surgical repair of posterior abdominal wall disruption followed by rehabilitation. Br J Sports Med 2003;37(1):54–8.
50. Brannigan AE, Kerin MJ, McEntee GP. Gilmore's groin repair in athletes. J Orthop Sports Phys Ther 2000;30(6):329–32.
51. Brown RA, Mascia A, Kinnear DG, et al. An 18-year review of sports groin injuries in the elite hockey player: clinical presentation, new diagnostic imaging, treatment, and results. Clin J Sport Med 2008;18(3):221–6.
52. Kluin J, den Hoed PT, van Linschoten R, et al. Endoscopic evaluation and treatment of groin pain in the athlete. Am J Sports Med 2004;32(4):944–9.

Downloaded from ClinicalKey.com at Ohio State University Libraries August 26, 2016.
For personal use only. No other uses without permission. Copyright ©2016. Elsevier Inc. All rights reserved.